

17 March 2023

Matamata Veterinary
Services Ltd
362 Hinuera Road West
RD2, Matamata 3472
New Zealand
Tel 07 888 8193

SURGICAL REPORT

Re: Sheezababe – Tivaci 2021 colt

Brands: Left shoulder: WS Right shoulder: 143 over 1

Microchip: 985125000125160

Owner: Waikato Stud

Referring vet: Dr Trent Jorgensen

On 16 March 2023 the above-described horse underwent arthroscopic surgery of the left stifle joint for treatment of an osteochondritis dissecans (OCD) lesion on the lateral trochlear ridge of the femur.

The joint was examined using the standard arthroscopic approach to the dorsal aspect of the femoro-patellar joint. The lesion consisted of several unattached osteochondral fragments overlying an irregular subchondral bone defect. The fragments were removed, and the remaining defect was debrided to expose healthy subchondral bone. The joint was flushed with sterile saline and recovery from anaesthesia was uneventful.

Management:

1. Rest: Please maintain on box rest for four weeks, followed by four weeks in a small yard before going back out into a small paddock.
2. Bute: Please give 10ml by mouth once daily starting tomorrow morning (18 March 2023) for another three days.
3. Antibiotics: Please give 33ml Depocillin intramuscularly morning and night (starting tonight) for another 2 days.
4. Suture removal: Please have your vet remove the sutures on Monday 27 March 2023.

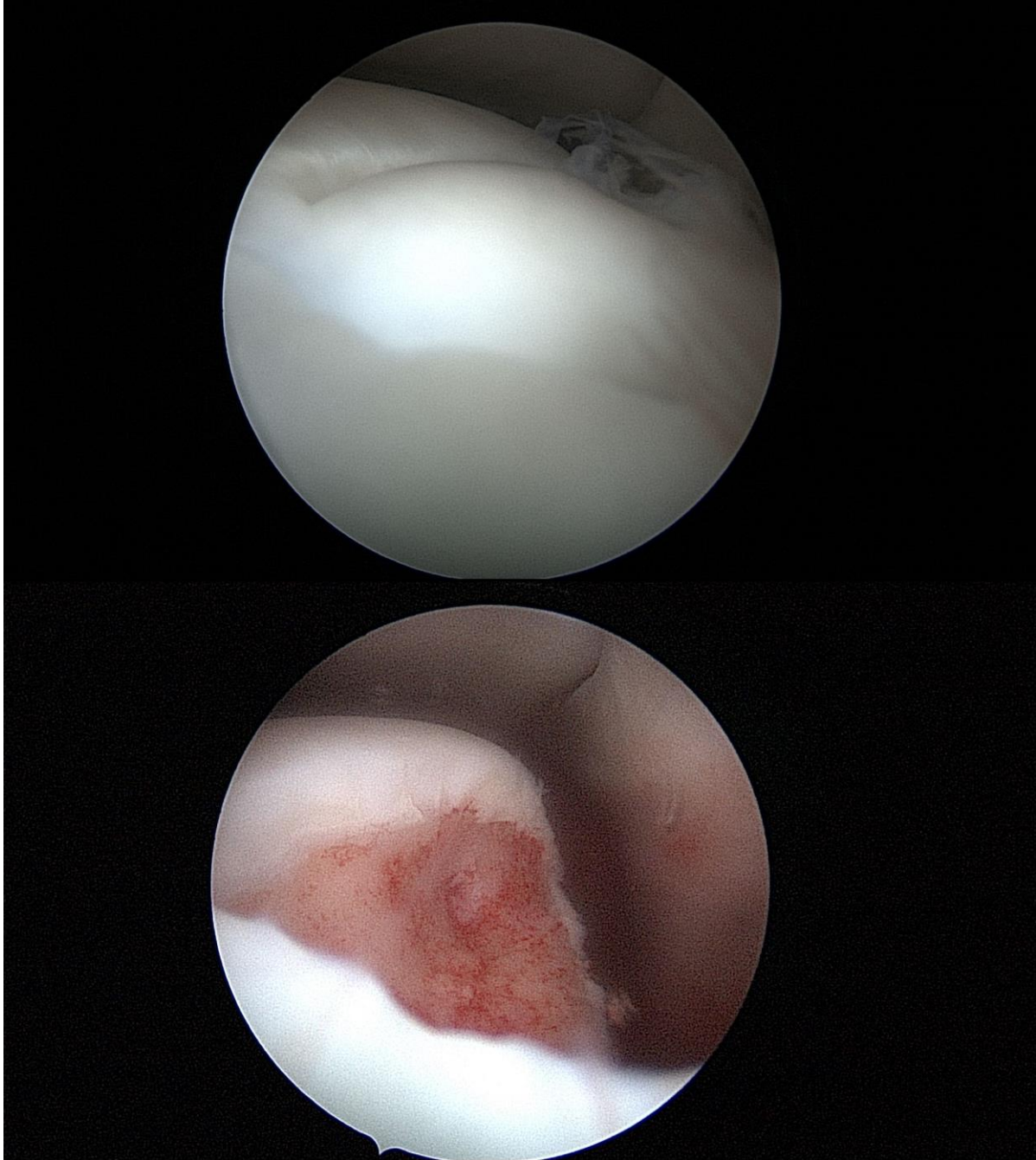
Intravenous and intramuscular injections have been administered to this horse. Please monitor the catheter, injection sites, and incisions closely. Please contact your veterinarian if there are any signs of lameness, heat, pain, swelling and/or discharge.

Yours sincerely



Andrea Ritmeester BVSc (Hons) MS DipACVS
Registered Specialist in Equine Surgery

Please ensure that this report is forwarded to the horse's owner(s) and the person(s) responsible for the future care of the horse, as well as to the insurer, if applicable.



Left stifle joint: OCD lesion on lateral trochlear ridge of the femur before (top) and after removal (bottom).

Please ensure that this report is forwarded to the horse's owner(s) and the person(s) responsible for the future care of the horse, as well as to the insurer, if applicable.

Dave Keenan BVSc MANZCVS
Andrea Ritmeester BVSc (Hons) MS DipACVS
Leigh de Clifford BVSc CertAVP PGDipVPS MSc
Barbara Hunter DVM MS MANZCVS DACVS-LA
Babiche Heil DVM (Hons) MSc Dipl ACT MANZCVS
Bill Ewen BVSc (Dist)

Rochelle Kerr BVSc BAgSci DipAgSci CVA
Roisin McQuillan MVB BAgSc
Therese Ritson BVSc
Caroline Thompson BVSc (Dist)
Ian Heyns BSc Agric BVSc
Tracey Kerr MVB MANZCVS

Jess Connell BVSc
Michelle Badke BVSc
Anna Schroeder BVSc BSc
Stephanie Brooks DVM BVetBiol
Rebecca Dinsdale BVSc MRCVS
Frances Peat BVSc MS PGCertSc DACVSMR